CED
Clinical and Experimental Dermatology

CPD

Motor nerves of the head and neck that are susceptible to damage during dermatological surgery

S. M. Brown, T. Oliphant and J. Langtry

Department of Dermatology, Royal Victoria Infirmary, Newcastle Upon Tyne, UK

doi:10.1111/ced.12374

Summary

As the incidence of non melanoma skin cancer rises, dermatologists will increasingly be called upon to perform excisions in the head and neck region. Damage to the motor nerves of the head and neck represents an important adverse event for patients, and a source of litigation for surgeons. Understanding the anatomy of this region is key to counselling patients about the possibility of motor nerve injury associated with particular skin surgical procedures. We describe the anatomy of the motor nerves of the head and neck that are most vulnerable to injury during dermatological surgery. The consequences of injury are outlined, and the surface anatomy and anatomical landmarks that may be used to identify the relevant danger zones are described.

Introduction

Dermatologists have a key role in the diagnosis and surgical management of skin cancer. A good understanding of the anatomy of the head and neck, including the surface anatomy of the motor nerves and the anatomical planes that must be traversed in order to encounter these structures, is needed in order to safely operate in this region. An important concept in understanding the head and neck anatomy is the superficial musculoaponeurotic system (SMAS),[1,2] a layer of superficial fascia that envelops and links the facial expression muscles with each other and with the overlying skin. A detailed description of this can be found in a number of texts on head and neck anatomy.[3,4]

Correspondence: Dr Sarah M. Brown, Department of Dermatology, Newcastle Upon Tyne Hospitals NHS Foundation Trust, Royal Victoria Infirmary, Queen Victoria Road, Newcastle Upon Tyne, NE1 4LP, UK
E-mail: sarah.brown16@nuth.nhs.uk

Conflict of interest: the authors declare that they have no conflicts of interest.

Accepted for publication 6 February 2014

Nerves that may be affected during dermatological surgery

Facial nerve (cranial nerve VII)

The facial nerve enters the parotid gland at the midpoint of a line connecting the tragus with the angle of the mandible. Within the parotid gland, the facial nerve divides into five branches (temporal, zygomatic, buccal, marginal mandibular and cervical) (Fig. 1). At this point, the nerve is separated from the subcutaneous fat only by a thin layer of glandular tissue and parotid fascia (a component of SMAS). After leaving the parotid gland, the branches of the facial nerve lie deep to the SMAS and enter the muscles of facial expression from their deep surface. The branches of the facial nerve are therefore well protected during surgical procedures that are no deeper than fat. However, it is important to note that there can be minimal thickness of the fat layer at certain sites such as the temple, and also at other sites in elderly patients.

The two branches of the facial nerve most susceptible to injury during dermatological surgery are the temporal branch as it crosses the zygomatic arch, and the marginal mandibular branch along the inferior border of the mandible. These branches typically have

© 2014 British Association of Dermatologists

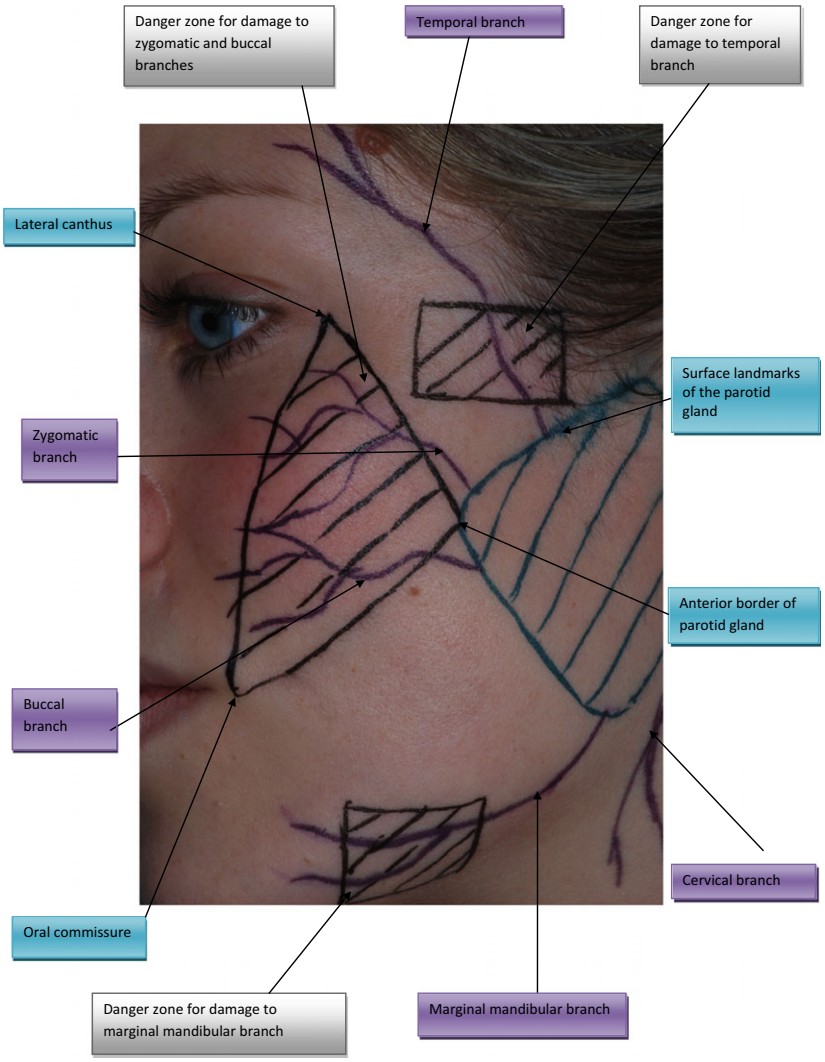

Figure 1 Branches of the facial nerve. The danger zone for damage to the buccal and zygomatic nerves lies in a triangular area between the anterior border of the parotid gland and a line drawn from the lateral canthus to the oral commissure. The danger zones for the marginal mandibular branch and temporal branch are shown as well as the branches of the facial nerve All photographs are of one of the authors (SBB); permission given for publication.

only a few rami, therefore damage to one or more of them is likely to result in functional impairment. The buccal and zygomatic branches form an interconnecting network across the mid face, and injury is therefore less likely to result in clinically apparent weakness. Damage to the cervical branch is of minimal clinical importance, and therefore is not discussed further here.

Temporal branch of the facial nerve

The temporal (or frontal) branch of the facial nerve innervates the frontalis, the upper fibres of the orbicularis oculi, the corrugator supercilii, and the anterior and superior auricular muscles. After emerging from the parotid gland, the nerve travels diagonally across the temple, where it lies between the superficial temporal fascia (a component of SMAS) and the deep temporal fascia. The temporal branch of the facial nerve divides into 3–5 rami as it crosses the middle third of the zygomatic arch. At this point, the nerve is most superficial and susceptible to damage. The approximate course of the temporal branch of the facial nerve can be projected on the skin by a line drawn 5 mm below the tragus to a point 15 mm above the lateral eyebrow[5] (Fig. 2).

Damage to the temporal branch of the facial nerve results in a quizzical expression, caused by inability to raise the eyebrow. Over time, as the denervated muscle atrophies, patients develop eyebrow ptosis, which, when combined with the redundant upper eyelid skin in older patients, may result in significant obscuring of the superolateral visual field. It may be possible to elevate a ptotic eyebrow with various combinations of direct browlifts, indirect browlifts and blepharoplasty,[6] and thus improve this problem.

 © 2014 British Association of Dermatologists

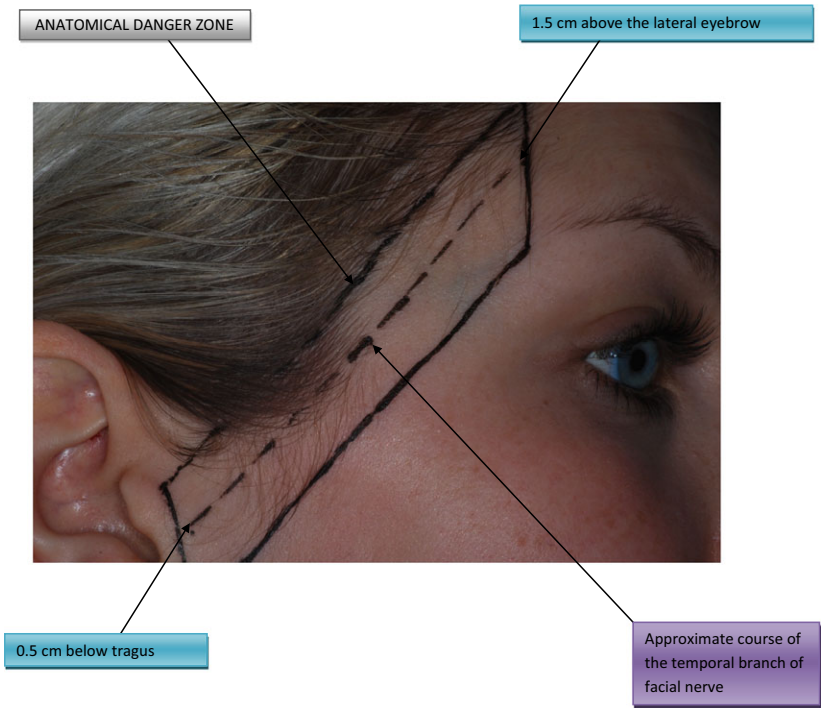

Figure 2 Course of temporal branch of facial nerve, from a point 5 mm below the tragus to a point 15 mm above the lateral eyebrow. The temporal branch is at most at risk when crossing the zygomatic arch.

Marginal mandibular branch of the facial nerve

The marginal mandibular branch of the facial nerve exits the parotid gland at the angle of the jaw. It divides into two or more rami, and travels anteriorly along the ramus of the mandible to supply the depressor anguli oris, the depressor labii inferioris, the mentalis and part of the orbicularis oris.[7] Posterior to the facial artery, the marginal mandibular branch may be variable in location. In some patients, the nerve is found up to a centimetre below the inferior border of the mandibular ramus,[8] and according to some authors, from 20 to 40 mm below the mandible, with marked variation in location occurring with changes in the position of the patient's head.[9] Anteriorly, the nerve lies beneath and is protected by the platysma. However, it is important to recognize that the platysma undergoes atrophy with age, and may be extremely thin or even absent. Damage to this nerve results in an inability to depress the lip and consequently an asymmetrical smile.[10]

Buccal and zygomatic branches of the facial nerve

The buccal branch of the facial nerve emerges from the anterior end of the parotid gland, and travels anteriorly to innervate the orbicularis oris, the elevators of the upper lip, the buccinator and some of the nasal muscles. Damage is rare, but may result in difficulties with chewing food due to paralysis of the buccinator, allowing food to escape from between the molars. Patients may also have an asymmetrical smile. The zygomatic branch of the facial nerve exits the parotid gland near its upper pole, and travels across the zygomatic arch to the lateral angle of the orbit. It innervates the lower part of the orbicularis oculi, the procerus, some of the nasal muscles, and some of the mouth elevators. Damage may result in diminished ability to close the eyelid and development of an asymmetrical smile. The danger zone for damage to these branches lies in a triangular area between the anterior border of the parotid gland and a line drawn from the lateral canthus to the oral commissure[11] (Fig. 1).

Spinal accessory nerve

The posterior triangle of the neck is defined by the posterior border of the sternocleidomastoid, the anterior border of the trapezius, and the clavicle. The spinal accessory nerve enters the posterior triangle of the neck from under the posterior border of the sternocleidomastoid, roughly at its mid point. It then crosses the floor of the posterior triangle, before leaving the posterior triangle under the trapezius. In the posterior triangle of the neck, the spinal accessory nerve occupies a relatively

© 2014 British Association of Dermatologists

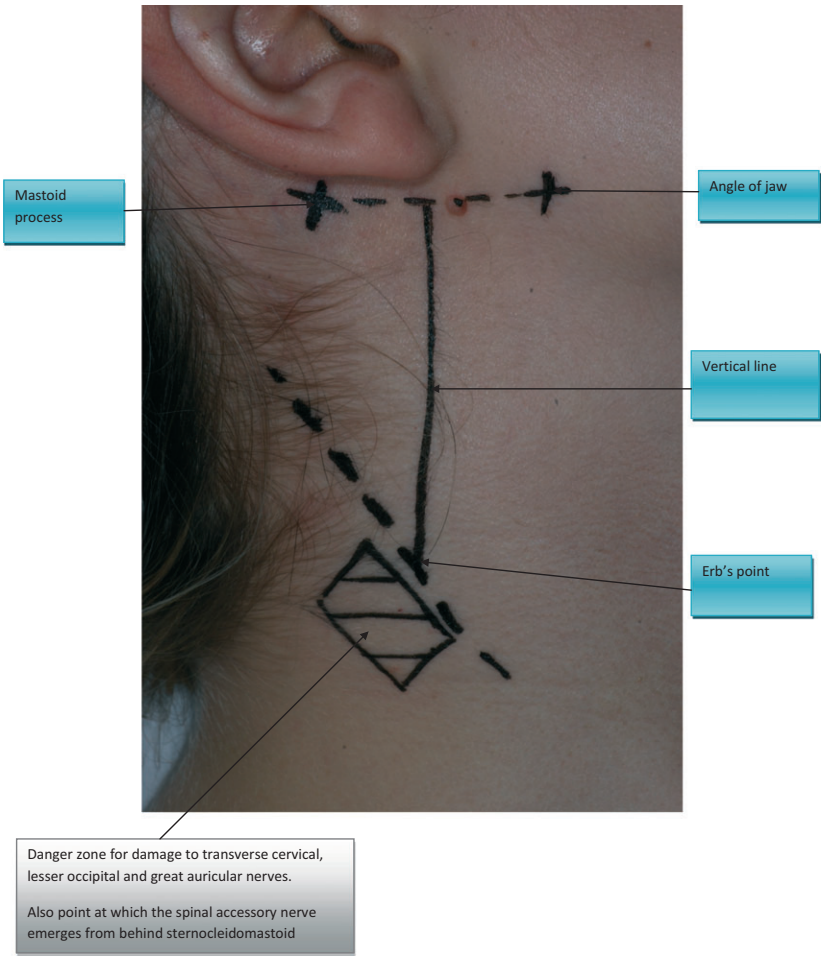

Figure 3 Erb's point can be identified by drawing a vertical line from the midpoint of a line between the angle of the jaw and the mastoid process of the temporal bone. This point indicates the location of several important sensory nerves: the transverse cervical, lesser occipital and great auricular nerves. Most importantly, it is also the point at which the spinal accessory nerve emerges from the posterior border of sternocleidomastoid.

superficial location between the superficial and prevetertebral layers of the deep cervical fascia.

Dropping a vertical line from the midpoint of a line between the angle of the jaw and the mastoid process of the temporal bone identifies Erb's point (Fig. 3). This landmark indicates the location of several important sensory nerves, including the transverse cervical, lesser occipital and great auricular nerves, but most importantly, the point at which the spinal accessory nerve emerges from behind the sternocleidomastoid. An alternative method of location of the accessory nerve is to draw a line posteriorly from the thyroid notch across the posterior triangle; 20 mm above this line identifies the point where the nerve emerges from behind sternocleidomastoid and 20 mm below this point the nerve passes below the trapezius.[12] Damage causes paralysis of the trapezius muscle. This results not only in an inability to fully elevate or abduct the shoulder, but also in winging of the scapula, chronic aching due to stretching of the shoulder capsule, and paraesthesiae.

Conclusion

In this review article, we have presented the motor nerves of the head and neck that are most susceptible to damage during dermatological surgery. In general, incision and undermining at the level of subcutaneous fat is unlikely to result in damage to the motor nerves, as these lie beneath or within the SMAS.

Learning points

- Incisions and undermining within the subcutaneous fat above SMAS will not result in damage to motor nerves.
- The temporal branch of the facial nerve runs deep to the SMAS, and is most at risk as it crosses the zygomatic arch.
- Damage to the temporal branch of the facial nerve may result in an ipsilateral eyebrow ptosis and obscuring of the superolateral visual field.

 © 2014 British Association of Dermatologists

- The marginal mandibular branch of the facial nerve is vulnerable to damage along the inferior edge of the body of the mandible.
- Damage to the marginal mandibular branch of the facial nerve results in an asymmetrical smile.
- The spinal accessory nerve lies in the posterior triangle of the neck, and may be identified by Erb's point.

References

1 Mitz V, Peyronie M. The superficial musculo-aponeurotic system (SMAS) in the parotid and cheek area. *Plast Reconstr Surg* 1976; **58**: 80–8.
2 Jost G, Levet Y. Parotid fascia and face-lifting: a critical evaluation of the SMAS concept. *Plast Reconstr Surg* 1984; **74**: 42–51.
3 Salasche SJ, Bernstein G, Senkarik M. *Surgical Anatomy of the Skin*. Norwalk: Appleton and Lange, 1988.
4 Larrabee WF, Makielski KH, Henderson JL. *Surgical Anatomy of the Face*. 2nd edn (Mikhli K, ed). Philadelphia: Lippincott Williams & Wilkins, 2004.
5 Pitanguy I, Ramos SA. The frontal branch of the facial nerve: the importance of its variations in face lifting. *Plast Reconstr Surg* 1966; **38**: 352–6.
6 Grabski WJ, Salasche SJ. Management of temporal nerve injuries. *J Dermatol Surg Oncol* 1985; **11**: 145–51.
7 Dingman RO, Grabb WC. Surgical anatomy of the mandibular ramus of the facial nerve based on the dissection of 100 facial halves. *Plast Reconstr Surg* 1962; **29**: 266–72.
8 Potgieter W, Meiring JH, Boon JM *et al.* Mandibular landmarks as an aid in minimising injury to the marginal mandibular branch: a metric and geometric anatomic study. *Clin Anat* 2005; **18**: 171–8.
9 Baker DC, Conley J. Avoiding facial nerve injuries in rhytidectomy. *Plast Reconstr Surg* 1979; **64**: 781–95.
10 Moffat DA, Ramsden RT. The deformity produced by a palsy of the marginal mandibular branch of the facial nerve. *J Laryngol Otol* 1977; **91**: 401–6.
11 Bernstein G. Surface landmarks for the identification of key anatomic structures of the face and neck. *J Dermatol Surg Oncol* 1986; **12**: 722–6.
12 King IJ, Motta G. Iatrogenic and spinal accessory nerve palsy. *Ann R Coll Surg Engl* 1983; **65**: 35–7.

CPD questions

Learning objective

To understand the anatomy of the motor nerves of the head and neck and their importance in skin surgical procedures.

Question 1

Which of the following is not a branch of the facial nerve?
a) Temporal.
b) Infraorbital.
c) Zygomatic.
d) Buccal.
e) Cervical.

Question 2

In which anatomical plane can the temporal branch of the facial nerve be found as it crosses the temple?
a) Beneath the deep temporal fascia/periosteum.
b) Within subcutaneous fat.
c) On the superficial aspect of the superficial musculo-aponeurotic system.
d) Between the superficial musculoaponeurotic system and the deep temporal fascia.
e) Within the superficial musculoaponeurotic system.

Question 3

Which of the following muscles does the marginal mandibular branch of the facial nerve not supply?
a) Depressor anguli oris.
b) Depressor labii inferioris.
c) Mentalis.
d) Risorius.
e) Orbicularis oris.

Question 4

Which of the following nerves is not found at Erb's point?
a) Spinal accessory nerve.
b) Transverse cervical nerve.
c) Great auricular nerve.
d) Auriculotemporal nerve.
e) Lesser occipital nerve.

Question 5

Which of the following is a consequence of damage to the marginal mandibular branch of the facial nerve?
a) Difficulty chewing food.
b) Difficulty closing the eyelid.
c) Difficulty raising the eyebrow.

© 2014 British Association of Dermatologists

d) An asymmetrical smile.
e) Paralysis of platysma.

Instructions for answering questions

This learning activity is freely available online at http://www.wileyhealthlearning.com/ced.

Users are encouraged to

- Read the article in print or online, paying particular attention to the learning points and any author conflict of interest disclosures.
- Reflect on the article.
- Register or login online at www.wileyhealthlearning.com/ced and answer the CPD questions.
- Complete the required evaluation component of the activity.
- Once the test is passed, you will receive a certificate and the learning activity can be added to your RCP CPD diary as a self-certified entry.

 © 2014 British Association of Dermatologists